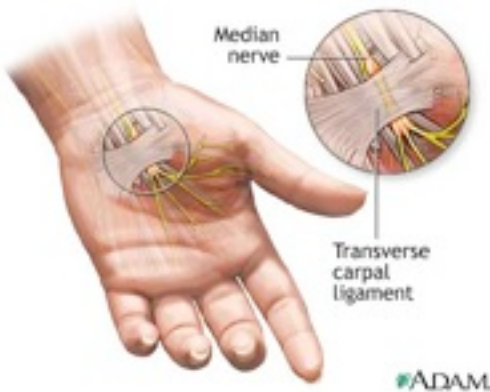


# Carpel Tunnel Syndrome

Carpal tunnel syndrome (CTS) is a debilitating disease entity that can severely impact the patient's quality of life. It is characterized by symptoms including pain of the hand and wrist, in addition to tingling and numbness along the median nerve distribution. Until recently, surgery was the primary option available to patients seeking a long term solution to this problem. At Bayswater Therapy we have treated many patients with CTS and the results have been uniformly outstanding. At this time we continue to conduct ongoing studies utilizing Low Intensity Laser Therapy (LILT) and Neuromuscular Therapy in the treatment of CTS.

## Anatomy

The carpal tunnel is a somewhat narrow canal in the wrist that is surrounded on three sides by the palmar aspect of the carpal bones and covered by the flexor retinaculum (Figure 1). In addition to the median nerve, the flexor tendons also traverse this pathway.



## Etiological Factors

CTS occurs when the median nerve becomes compressed at the wrist (Figure 2). This nerve controls sensation to digits 1, 2 and 3, as well as the lateral aspect of digit 4. In addition, it controls the motor function of many small muscles in the hand. The etiological factors with regard to CTS consist of a combination of causes that increase pressure on the median nerve and tendons in the carpal tunnel, rather

than just the nerve per se. These include a genetic - anatomical variation predisposing to a restricted carpal tunnel dimension. Many cases of CTS are caused by repetitive motion of the wrist and digits. At one time the belief was that computer/ keyboard work provoked and even caused CTS; recently two large studies<sup>1,2</sup> report that this concept is not correct and computer/keyboard work may not even be a factor in the development of CTS. There are many other factors that contribute to the cause of CTS including:

- Trauma to the wrist (i.e. sprain, fracture, contusion, etc. with resulting edema)
- Hyperactivity of the pituitary gland
- Hypothyroidism
- Rheumatoid arthritis
- Mechanical problems of the wrist
- Work stress (i.e. repeated use of vibrating tools)
- Fluid retention during pregnancy
- Development of a cyst or tumor in the canal

## Diagnosis

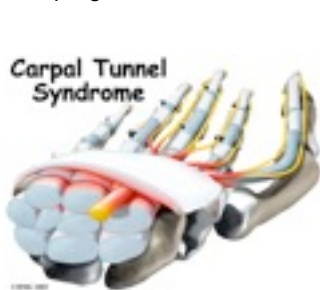Early diagnosis is important in minimizing long term damage to the median nerve. A thorough physical examination is required to determine the correct diagnosis. Testing for both Tinel's sign and Phalen's maneuver can often indicate the extent of the disease. It is appropriate to use nerve conduction tests to confirm a diagnosis and periodically test the progress with regard to the status of the median nerve. A delayed response time infers the correct diagnosis in addition to providing an accurate representation of the degree of severity. In excess of 60% of patients that present at our clinic with presumptive CTS are inappropriately diagnosed. On the other hand approximately 20% of patients are borderline and may have concomitant pathologies along with compression of the median nerve. This can make a definitive diagnosis difficult to achieve in some instances. One must always rule out lesions of the cervical spine, brachial plexus, shoulder and elbow in addition to other conditions existing at the wrist. The most common of these of course is

degenerative osteoarthritis of the cervical spine with nerve root compression. Ulnar neuritis at the elbow must also be considered and again may coexist with CTS. Again a careful clinical examination along with a nerve conduction test aid considerably in establishing the correct diagnosis, which sometimes may be neither simple nor straightforward. In certain situations, a test treatment of 5 sessions can be applied for CTS to determine if significant improvement occurs. At our clinic this is carried out utilizing the BioFlex Low Intensity Laser Therapy System and if after several sessions (5+) significant improvement occurs, this will confirm the diagnosis. Although remote, other causes may be intra-cranial or in the spinal cord itself. Always remember to rule out other etiologies and attempt to achieve positive confirmation of the diagnosis utilizing a nerve conduction test.

## Prevention and Treatment

Prevention of CTS is often difficult for people who earn a livelihood utilizing their hands. Avoiding forceful, repetitive activities of the hand and wrist can often relieve symptoms, but on resumption of these activities the symptoms generally return. Rest periods can be implemented throughout the work-day with multiple mini-breaks being more effective than less frequent longer breaks. Decreasing the stress on the structures of the wrist by constructing ergonomic work stations has also been shown to decrease the prevalence of CTS. Some authorities have suggested that dietary factors may be responsible for the severity of the symptoms. Analgesics, anti-inflammatories and vitamins have been utilized to improve symptoms although no resolution of the underlying pathology is achieved. In some centers the majority of patients with CTS are prescribed rest to the affected area for several weeks. Unfortunately this means that patients are unable to work and the employer must at least temporarily replace their positions. Splinting of the affected wrist during sleep and/or activities is also popular in some centers; however is not

advisable as it can cause muscle atrophy and again does not produce a permanent solution. Steroid injections into the carpal tunnel have also been shown to provide temporary relief (2 – 4 months). A review of the effectiveness of this solution revealed that at 18 months following the injection only 22% of patients were still symptom free.<sup>4</sup> Steroid injections mask the underlying pathology and as such should only be used as a temporary solution in acute cases. Prior to the adaptation of LILT, surgery was generally utilized by most medical practitioners, and is still performed in approximately 45% of CTS cases. This is only recommended when the disease has progressed from moderate to severe



status and has existed in excess of 6 months. Open release surgery is the traditional procedure to correct

this problem. This involves a long incision (2 - 4 inches) from the wrist into the palm and then dividing the flexor retinaculum, which relieves nerve compression. This surgery is often performed under local anesthesia on an outpatient basis. Endoscopic surgery can offer a more rapid recovery and less post operative pain than the traditional open release procedure. Whereas the endoscopic approach is less traumatic there is a somewhat higher risk of

inadvertent damage to the median nerve and other structures. Recurrence is rare and usually the result of an incorrect initial diagnosis. Nevertheless one third of patients continue to experience pain and functional impairment postoperatively.<sup>5</sup> Less than 40% of surgical patients achieve a completely normal functional status. In more than 5% of cases the surgery increases the severity of the condition.<sup>6,7</sup> Post surgical response may be slow and patients may be unable to work for prolonged periods with extensive rehabilitation required.<sup>7</sup>

### Low Intensity Laser Therapy in Treating CTS

At the Bayswater Therapy we have established Low Intensity Laser Therapy as the treatment of choice for carpal tunnel syndrome (CTS). The mechanism of action indicates that there is a relatively immediate reduction of pain and edema. There is also clear cut evidence suggesting that LILT aids in nerve regeneration.<sup>12</sup> Clearly LILT rapidly alleviates the symptoms of CTS and many other studies support this approach. For example a randomized double blind study carried out at General Motors in Detroit, Michigan used an 830nm diode laser and found decreased motor latency and improved grip strength following laser therapy.<sup>13</sup> More significantly, 72% of the workers treated with laser therapy returned to work compared with 41% of the workers in the control group. A recent additional analysis of the use of laser therapy in the treatment of CTS found an average success rate of 84% in the 171 cases studied.<sup>11</sup>

### Carpal Tunnel Syndrome Research at Meditech

Meditech Laser Rehabilitation Centre (manufacturer of BioFlex Low Intensity Laser Therapy System used at Bayswater Therapy Centre) last year invested in a state-of-the-art nerve conduction system to test median nerve transmission in this disease entity. The device utilized is the NC-stat System that is manufactured by Neurometrix (Neurometrix, Waltham, MA). The study in progress at Meditech tests the recovery of patients from CTS treated utilizing Low Intensity Laser Therapy. It is applied prior to initiating treatment, periodically during the course of treatment and at the termination when symptoms are no longer present. To illustrate, one patient tested had long standing bilateral CTS and had been subjected to surgery on her left wrist prior to presenting at our clinic. At the time of initial evaluation her right CTS was causing considerable discomfort accompanied by loss of sleep. The results from her initial nerve conduction test (Distal Motor Latency = 8.15ms; normal = 2.6 - 4.1ms) were indicative of a severe case of carpal tunnel syndrome. Due to the severity of the median nerve degeneration some cases require more prolonged treatments for total resolution of symptoms. Following four treatments of thirty minutes in duration a 20% reduction in her nerve conduction test was achieved (Distal Motor Latency = 6.90ms). This was accompanied by a significant reduction of pain and improved motor function. As research at Meditech continues we expect to periodically update our protocols to reflect clinical progress. In conclusion, it is apparent that Low Intensity Laser

### References

- Hedge A. Computer use and risk of carpal tunnel syndrome. *JAMA* 290 (14): 1854-1855, 2003.
- Stevens JC, Witt JR, Smith BE and Weaver AL. The frequency of carpal tunnel syndrome in computer users at a medical facility. *Neurology* 56(11): 1568-1570, 2001.
- Slater RR and Bynum DK. Diagnosis and treatment of carpal tunnel syndrome. *Orthop. Rev.* Oct 1095-1105, 1993.
- Gelberman GH, Aronson D and Weisman MH. Carpal tunnel syndrome: results from a prospective trial of steroid injections and splinting. *J. Bone Joint Surg. (Am.)* 62A: 1181, 1980.
- Duncan KH, Lewis RC Jr, Foreman KA and Nordyke MD. Treatment of carpal tunnel syndrome by members of the American Society for Surgery of the Hand: results of a questionnaire. *J Hand Surg (Am)* 12(3):384-91, 1987.
- Cseuz KA, Thomas JE, Lambert EH, Love JG, Lipscomb PR. Long-term results of operation for carpal tunnel syndrome. *Mayo Clin Proc.* 41(4): 232-41, 1966.
- Armstrong MB and Villalobos RE. Surgical treatment of carpal tunnel syndrome. In *Physical Medicine and Rehabilitation Clinics of North America*, Carpal Tunnel Syndrome. GH Kraft and EW Johnson. Philadelphia, Saunders. 529-539, 1997.
- US Department of Labor, Bureau of Labor Statistics Occupational injuries and illnesses in the United States by Injury. Washington DC: *US Government Printing Office*, 1991.
- Vennix MJ, Hirsh DD, Chiou-Tan FY and Rossi CD. Predicting acute denervation in carpal tunnel syndrome. *Arch. Phys. Med. Rehabil.* 8: 306-312, 1998.
- CTD's taking a bigger bite of corporate bottom line. *CTD News* 4:1, 1995.
- Naeser MA. Photobiomodulation of pain in carpal tunnel syndrome: Review of seven laser therapy studies. *Photomed. Laser Surg.* 24 (2): 101-110, 2006.
- Rochkind S. Photoengineering of neural tissue repair processes in peripheral nerves and the spinal cord: research development with clinical applications. *Photomed. Laser Surg.* 24 (2): 151-157, 2006.
- Anderson TE, Good WT, Kerr HH, Shumaker B, Bendick PJ and Nolte RG. Low level laser therapy in the treatment of carpal tunnel syndrome [Unpublished report]. Stafford, TX: Lasermedics, 1995.